

Cardiac Tamponade – A Case Report of an Atypical and Critical Presentation of Amoebic Liver Abscess

Sudha Chandelia*, Dinesh Kumar Yadav**

Abstract

Atypical clinical presentations pose a significant diagnostic challenge. We present a case that was admitted with cardiac tamponade and later diagnosed to have ruptured amoebic liver abscess. Cardiac tamponade resulted due to rupture of liver abscess into the pericardium. Our patient improved fully with pericardial drainage and medical management. This case highlights that in cases of pyopericardium coupled with fever and pain abdomen, liver abscess should strongly be suspected and ruled out.

Keywords: Cardiac Tamponade; Amoebic Liver Abscess; Hepato-Pericardial Fistula.

Introduction

Cardiac tamponade as atypical presentation or complication of amoebic liver abscess is rare especially in children. Such a different and rare presentation may result in missed diagnosis leading to a fatal outcome. This case teaches us that amoebic liver abscess (ALA) can present in emergency with cardiac tamponade and is fully treatable with a positive outcome.

Case report

A 6 year old boy was brought with difficulty in breathing for a few hours. In addition, he complained of fever for last 2 weeks and pain abdomen for 5 days. Fever was high grade not associated with chills/rigors. Pain was localized to upper abdomen. There was no history of cough, chest pain, diarrhoea, urinary complaints or bleeding from any site. On examination child was pale and had tachycardia with tachypnea (HR- 140/min, RR- 64/min). Pulses

were feeble and BP was 76/50 mmHg. JVP was raised and heart sounds were muffled. On chest examination, there was decreased air entry on left side. Abdomen was soft with liver extending 6cm below right costal margin (liver span-13 cm) and left lobe palpable 5 cm below xiphisternum. A provisional diagnosis of sepsis with pneumonia with pneumothorax/pyothorax/cardiac tamponade/pulmonary embolism was made. Supportive management was given in the form of oxygen therapy, fluid bolus and blood transfusion. Chest X ray showed cardiomegaly (CT ratio of 0.6). Echocardiography confirmed cardiac tamponade (pericardial effusion 1.8 cm in anterior space and collapse of right atrium and right ventricular free wall). A left lobe liver abscess measuring 6.2x5.8x5.0 cm close to the pericardial sac and a hepato-pericardial fistula was also seen. A pig tail catheter was inserted through percutaneous approach and 50 ml of anchovy sauce pus was aspirated. The child became hemodynamically stable with HR-106/min, RR-42/min, BP-98/58 mmHg, pulses became good volume. We did not find any other areas of pus collection like in muscle planes or joints. Subsequent ultrasonography showed a reduction in size of ALA. Total pus removed in the first 24 hours was a 90 ml. We did not have to drain the ALA separately. Blood culture and pus culture were sterile. A CECT scan did not show any extension of ALA and showed an improving course. Serology was positive for Entamoeba histolytica done by ELISA. Pigtail catheter was removed on day 5 and the child was discharged in good health.

Author Affiliation: *Assistant Professor, Division of Pediatric critical care **Assistant Professor, Division of pediatric cardiology, Department of Pediatrics, PGIMER and associated Dr. R.M.L Hospital, New Delhi, India.

Reprint request: Sudha Chandelia, 403, PGIMER, Academic Building, Dr. Ram Manohar Lohia Hospital, New Delhi, 110001.

E-mail: Sudhach83@rediffmail.com

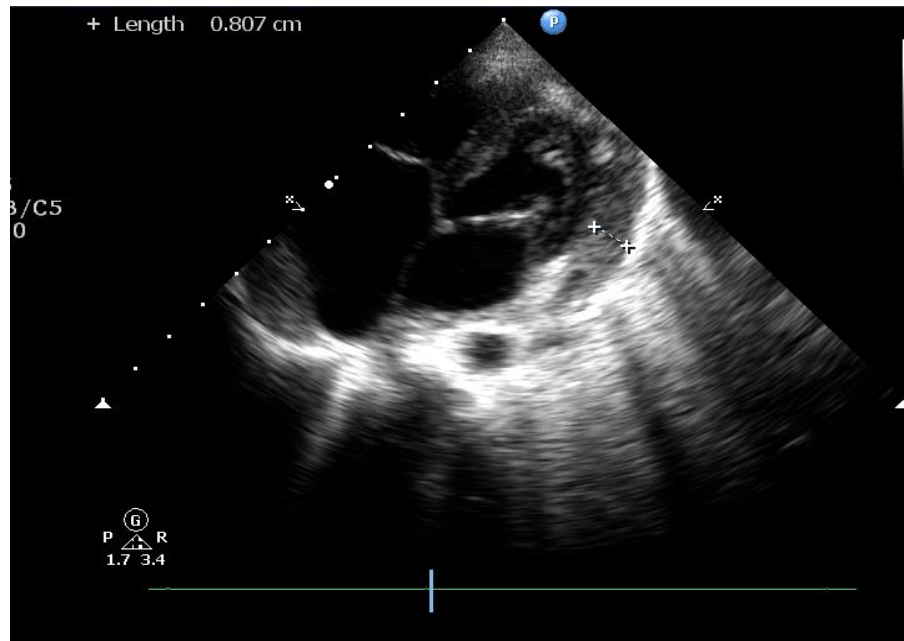


Fig. 1: Echocardiography showing pericardial effusion and hepato-pericardial fistula.

Discussion

Amoebiasis is a disease of tropical countries predominantly associated with lower socioeconomic strata and unhygienic conditions. ALA occurs in around 10% of all amoebiasis cases and mortality is certain in the untreated cases [1,2]. It may present a diagnostic challenge as it has diverse presentations resulting in delayed or missed diagnosis. In a study, the diagnosis of ALA was missed in 29% patients, particularly in those with atypical presentations [3]. Uncommon manifestations are due to complications resulting from the rupture of the abscess into the contiguous cavities like pleura, pericardium, peritoneum or compression of the tubular structures in the hepatic hilum or distant embolic dissemination. Reported atypical presentations of ALA are acute abdomen, jaundice/obstructive jaundice, amoebic pericarditis, PUO or silent abscess, hepatic coma and hepatorenal syndrome. ALA may mimic acute cholecystitis, perforated peptic ulcer, acute hepatitis, cirrhosis, hydatid cysts, pancreatic pseudocysts, pneumonia, and acute pleurisy with effusion, empyema, chronic lung disease, malignancy, tuberculosis and pyrexia of unknown origin [4]. In our case we also made a diagnosis of pneumonia with complications. ALA rupturing through the diaphragm has been shown in 7-20% and into the pericardium in less than 1% of cases [5, 6]. A study on emergency presentations of ALA showed an incidence of 12.7% of ruptured abscess (8% into the right pleura, 3.4% into the peritoneum and rest in both places) [4]. Most such cases of cardiac tamponade have been reported in

adults where rupture of the ALA occurred during hospital stay. Our case is unique as cardiac tamponade in cases of ALA is uncommon in children and rarely reported at presentation. Fortunately we had Echocardiography facility that can diagnose it speedily than a chest X-ray. In the event of acute catastrophe, it is better to do a diagnostic and subsequently a therapeutic pleural or pericardial tap if the delay in imaging is likely. Presence of fever and pain abdomen in cases presenting with cardiac tamponade is a good pointer towards diagnosis of ALA [3, 5]. Earlier case reports have correlated this complication to left lobe ALA similar to the present case. ALA can present with unusual symptoms and signs but is completely treatable if appropriate action is taken in time.

Conclusion

Infections like amoebic liver abscess can present in an emergency room. In cases of cardiac tamponade with prolonged fever and pain abdomen, a left liver lobe abscess should be ruled out.

References

1. Ralston KS, Petri WA Jr. Tissue destruction and invasion by *Entamoeba histolytica*. *Trends Parasitol*. 2011; 27(6):254-63.
2. WHO Meeting, Amoebiasis and its control, Bull World Health Organ, 1985,63,417-426.

3. Mukhopadhyay M, Saha AK, Sarkar A, Mukherjee S. Amoebic liver abscess: presentation and complications. *Indian J Surg.* 2010;72:37–41
4. Suthar KD. Clinical presentation and diagnostic difficulties in amoebic liver abscess. *NHL Journal of Medical Sciences.* 2014; 3(2):40-44.
5. Sharma N, Sharma A, Varma S, Lal A, Singh V. Amoebic liver abscess in the medical emergency of a North Indian hospital. *BMC Research Notes* 2010; 3:21.
6. Ibarra-Perez C. Thoracic complications of amoebic abscess of the liver: report of 501 cases. *Chest* 1981;79:672-7.
7. Chandran SR, Balakrishnan RK, Chinnasamy B, Srinivasan GK. Amoebic hepatopericardial fistula causing cardiac tamponade. *Ann Trop Med Public Health* 2012;5:387-9.

Indian Journal of Trauma and Emergency Pediatrics

Handsome offer for subscribers!!

Subscribe **Indian Journal of Trauma and Emergency Pediatrics** and get any one book or both books absolutely free worth Rs.400/-.

Offer and Subscription detail

Individual Subscriber

One year: Rs.7650/- (select any one book to receive absolutely free)

Life membership (valid for 10 years): Rs.76500/- (get both books absolutely free)

Books free for Subscribers of **Indian Journal of Trauma and Emergency Pediatrics**. Please select as per your interest. So, don't wait and order it now.

Please note the offer is valid till stock last.

CHILD INTELLIGENCE

By Dr. Rajesh Shukla

ISBN: 81-901846-1-X, Pb, vi+141 Pages

Rs.150/-, US\$50/-

Published by **World Information Syndicate**

PEDIATRICS COMPANION

By Dr. Rajesh Shukla

ISBN: 81-901846-0-1, Hb, VIII+392 Pages

Rs.250/-, US\$50

Published by **World Information Syndicate**

Order from

Red Flower Publication Pvt. Ltd.

48/41-42, DSIDC, Pocket-II, Mayur Vihar, Phase-I

Delhi - 110 091 (India)

Tel: 91-11-22754205, 45796900, Fax: 91-11-22754205

E-mail: redflowerppl@gmail.com, redflowerppl@vsnl.net

Website: www.rfppl.co.in

Subscription Form

I want to renew/subscribe international class journal "**Indian Journal of Trauma and Emergency Pediatrics**" of Red Flower Publication Pvt. Ltd.

Subscription Rates:

- India: Institutional: Rs.8500, Individual: Rs.7650, Life membership (10 years only for individuals) Rs.76500.
- All other countries: \$302

Name and complete address (in capitals):

Payment detail:

Demand Draft No.

Date of DD

Amount paid Rs./USD

1. Advance payment required by Demand Draft payable to Red Flower Publication Pvt. Ltd. payable at Delhi.
2. Cancellation not allowed except for duplicate payment.
3. Agents allowed 10% discount.
4. Claim must be made within six months from issue date.

Mail all orders to

Red Flower Publication Pvt. Ltd.

48/41-42, DSIDC, Pocket-II, Mayur Vihar Phase-I, Delhi - 110 091 (India)

Tel: 91-11-22754205, 45796900, Fax: 91-11-22754205

E-mail: redflowerppl@vsnl.net, redflowerppl@gmail.com

Website: www.rfppl.co.in